

## Human Skeletal Remains of the Medieval and Edo Periods from the Obusato Site 20th Locality, Saitama Prefecture

Yousuke Kaifu<sup>1</sup> and Hiroyuki Yanagida<sup>2</sup>

<sup>1</sup> Department of Anthropology, National Science Museum, 3–23–1 Hyakunincho, Shinjuku-ku, Tokyo, 169–0073 Japan  
e-mail: kaifu@kahaku.go.jp

<sup>2</sup> Urawa City Iseki-Chosakai, 4–4–20 Kamikizaki, Saitama City, Saitama Prefecture, 338–0804 Japan

**Abstract** Human remains unearthed from the graveyard at the Obusato Site 20th Locality are described. Most of these remains belong to the latest Muromachi period and some to the Early Edo period. Although the preserved specimens are mostly fragmentary, they show a series of previously documented characteristics of the Medieval people of the Kanto region. The condition of oral hygiene is inferred to have been relatively poor, and average longevity of the population was probably significantly shorter than the Japanese people of modern times. The small sample from the site gives some suggestions regarding aspects of the organization of the burial in this period.

**Key words:** Human remains, Medieval period, Edo period, Japan

The Obusato Site is located on a plateau at Aza-Obusato, Oaza-Mimuro, Saitama (formerly Urawa) City, Saitama Prefecture. The 20th Locality is in an eastern flat area of this site complex, and is about 14 m above sea level. From 1964 to 1997, the excavation had been conducted at the Obusato Site from the Locality 1 through 27. In this site complex, archeological remains of the Paleolithic, from Early through Late Jomon, from Late Yayoi through Early Kofun, Heian, and from Medieval through Edo periods have been discovered. The graveyard from the Medieval to Edo periods was found at the 20th Locality in 1994. In this graveyard, 66 cremation and 114 burial graves were distributed within the area of 50 m N–S and 37 m E–W. The graveyard was divided into lots by three ditches. The overlapping relations between the cremation and burial graves indicated that the former is older than the later, although both types of the grave may have been made simultaneously during the transitional period from the cremation to burial. The period of each grave was inferred based on the type of associated coins. However, some of the graves

which were judged as those of the Medieval period may actually belong to the Edo period because the coin of the Edo period was began to be made 33 years after the beginning of the period. All the remains are presently housed at Department of Anthropology, National Science Museum, Tokyo. Original descriptions of these remains appear in the excavation report by the Urawa City Iseki-Chosakai (Kaifu and Yanagida, 2001).

### Materials and Methods

Fifty-five human skeletal remains were unearthed from the above-described graveyard. Table 1 is a list of the human remains, the individual's estimated age and sex, and period of the grave. The preservation of each human remain is summarized in Table 2. The age estimation in Table 1 is based on the following age categories: early adulthood, 20–40 years; late adulthood, older than 40 years; adult, 20 years or older; young adult, 16–30 years. Age estimation for subadult individuals was based on Ubelaker (1989)'s crite-

Table 1. List of the excavated human remains.

Specimen	Sex	Basis of sex estimation	Age	Basis of age estimation	Period	Remarks
Cremation 4	?		Young adult~	Epiphyseal fusion	?Latest Muromachi	
Cremation 5	?		Early adulthood	M3, TW	?Latest Muromachi	
Cremation 10	?		?		?Latest Muromachi	Less sign of burning on the cranium Identification impossible
Cremation 13						
Cremation 14	?		Adult	M3 alveolus		Identification impossible
Cremation 24						
Cremation 35	?		Early adulthood	M3, TW	?Latest Muromachi	
Cremation 41	?		Adult	Femoral morphology	?Latest Muromachi	
Cremation 43	?		?			
Burial 1	?		Adult	TW	?Latest Muromachi	
Burial 2	?F	Gracile mandible	Early adulthood	M3, TW	?Latest Muromachi	
Burial 3	?		Early to late adulthood	M3, TW	?Latest Muromachi	
Burial 9	?		Early to late adulthood	TW	Latest Muromachi	
Burial 13	?M	Overall size	Early adulthood	M3, TW, AS		
Burial 18	?		Early to late adulthood	M3, TW	Latest Muromachi~	
Burial 22	?M	Overall size	Early to late adulthood	TW	?Latest Muromachi~	
Burial 24	?		Young adult	TW	?Latest Muromachi	
Burial 26	F	MP	Early to late adulthood	M3, TW	?Latest Muromachi~	
Burial 27	?		Early adulthood	TW	?Latest Muromachi~	
Burial 30	M	Glabellar swelling	Early to late adulthood	M3, TW, CS	Latest Muromachi~	
Burial 34	?		Early to late adulthood	M3, TW	?Latest Muromachi	
Burial 35	?		Early adulthood	M3, TW		
Burial 36	M	Mandibular morphology	Early adulthood	M3, TW, CS	?Latest Muromachi	
Burial 43	?		Early adulthood	TW	?Early Edo	
Burial 44	?		Adult	TW	?Latest Muromachi~	
Burial 45	?		Early adulthood	M3, TW	?Latest Muromachi~	
Burial 63	?		Early adulthood	M3, TW	Latest Muromachi~	
Burial 64						
Burial 65	M	MP	Early adulthood	M3, TW	?Latest Muromachi	
Burial 66	?		14-16 years	DV	Latest Muromachi~	
Burial 70	?		Early adulthood	TW		
Burial 72	?		Early to late adulthood	TW		
Burial 73	?		Early to late adulthood	TW		Identification impossible

## Human Remains from the Obusato Site 20th Locality

29

Table 1. (Continued)

Specimen	Sex	Basis of sex estimation	Age	Basis of age estimation	Period	Remarks
Burial 74	M	MP, Femoral morphology	Late adulthood	M3, TW	Latest Muromachi to Early Edo	
Burial 77	F	MP	Early adulthood	M3, TW, CS		
Burial 78	?F	Gracile mandible	Early adulthood	M3, TW		
Burial 80	?F	MP	Early adulthood	M3, TW	Latest Muromachi~	
Burial 81	?		Early adulthood	M3, TW		
Burial 82	F	Glabella, Chin development	Early adulthood	M3, TW	Latest Muromachi~	
Burial 83	?		Early adulthood	M3, TW	?Latest Muromachi	
Burial 84	M	Tooth size	Early adulthood	M3, TW	Latest Muromachi~	
Burial 85	F	MP, Mandible	Early to late adulthood	M3, TW	Latest Muromachi~	
Burial 86	M	Overall size	Early adulthood	M3, TW	Latest Muromachi~	
Burial 87						Identification impossible
Burial 89	?		Young to early adulthood	TW	Latest Muromachi~	
Burial 91	?		Early adulthood	M3, TW	?Latest Muromachi	
Burial 92A	?		Early adulthood	M3, TW	Latest Muromachi~	
Burial 92B	?		Adult	TW	Latest Muromachi~	
Burial 93	M	Glabella	Early to late adulthood	M3, TW	Latest Muromachi~	?Lower than 92A
Burial 97	?		Early adulthood	M3, TW	Latest Muromachi~	Upper than 92A
Burial 100	?		?Adult	Lower limb bones	?Latest Muromachi	
Burial 101a	?M	Tooth size	15-20 years	DV	Latest Muromachi~	Double burial
Burial 101b	?F	Tooth size	Early adulthood	M3, TW	Latest Muromachi~	Double burial
Burial 104	?		Early to late adulthood	M3, TW	Latest Muromachi~	
Burial 105	?		Early to late adulthood	M3, TW	?Latest Muromachi	
Burial 106	?		Early adulthood	M3, TW	Latest Muromachi~	
Burial 107					?Latest Muromachi	Identification impossible
Burial 108	?		Early adulthood	M3, TW	Latest Muromachi~	?Long bones were burnt
Burial 109	?		14-16 years	DV		
Burial 115	?		5-8 years	DV		
Ditch 1						Identification impossible
T-27						Identification impossible

AS, auricular surface of the ilium; CS, cranial suture closure; DV, dental development; MP, mastoid process; TW, tooth wear.

Table 2. Preservation of the human remains.

Specimen	Cranial vault	Cranial base	Face	Mandible	Teeth	Clavicle	Scapula	Humerus	Radius	Ulna	Hand	Pelvis	Femur	Tibia	Fibula	Foot	Others
Cremation 4	×							×				×	×				Many unidentifiable frags
Cremation 5		×			×								×				Many unidentifiable frags
Cremation 10								×					×				Many unidentifiable frags
Cremation 14	×	×	×	×	×			×		△		×					Vertebrae, many frags
Cremation 35					△								△				
Cremation 41						×											Many unidentifiable frags
Cremation 43																	
Burial 1	×	×			△												Vertebrae
Burial 2		×	×		△												
Burial 3	×	×			△												
Burial 9		×			×												
Burial 13	×	△	×		△		×					×	△				Vertebrae, ribs
Burial 18					△								×				
Burial 22	×	×	×		△			×					×				
Burial 24					×												
Burial 26	×	×			×								×				
Burial 27		×			△										△		
Burial 30		×			△			△					×				
Burial 34	△	×	×		×				×				×				
Burial 35					△												
Burial 36	△	×	△		△		△	△	△	△		×	△	×	×		Vertebrae, ribs, patella
Burial 43					×												
Burial 44		×			×									×			
Burial 45					△												
Burial 63		×	×		△							×	×				
Burial 65		×	△		△							×	×				
Burial 66	×				△												
Burial 70					×												

## Human Remains from the Obusato Site 20th Locality

31

Table 2. (Continued)

Specimen	Cranial vault	Cranial base	Face	Mandible	Teeth	Clavicle	Scapula	Humerus	Radius	Ulna	Hand	Pelvis	Femur	Tibia	Fibula	Foot	Others
Burial 72					×												
Burial 73					×												
Burial 74		△	×	△	○							×		×		×	Vertebrae Vertebrae
Burial 77	×	×			△												
Burial 78	×	×	△	×	○								×				
Burial 80					○												
Burial 81					△												
Burial 82	×	×	△	×	○							×					Vertebrae
Burial 83	×	×	△	△	○							×					
Burial 84	×	×		×	○												
Burial 85	×	×		△	△												
Burial 86	×	×		×	△											×	
Burial 89	×	×			△												
Burial 91	×	×			△												
Burial 92A	×	×			△												
Burial 92B	×	×		×	△		×										
Burial 93	×	×	△	×	△												
Burial 97					△												
Burial 100					△												
Burial 101a				×	○												
Burial 101b				?	△												
Burial 104		×			△												
Burial 105	×	×	×	×	△												
Burial 106					△												
Burial 108				△	△												Axis
Burial 109					○			×									
Burial 115					△												

○, well-preserved; △, partly preserved; ×, poorly preserved; (blank), no remains.

ria of dental development stage. Meindl and Lovejoy (1985)'s work on cranial suture closure is referred to for the age estimation of the adult individuals. The age estimation from the degree of occlusal tooth wear was done referring to the wear severity of small specimens whose age was reliably inferred by associated cranium or pelvis. The methods of Fujita (1949) were used for dental measurement.

The human remains were generally fragile, and most of the teeth and a part of the bones were strengthened by thin solution of butvar (Monsanto Chemical Co.) Thick solution of butval is used as glue for restoration of the broken pieces. These can easily be corrected by using acetone.

### Description and Discussion

Table 3 shows the preservation of the dentition and dental measurements. Measurements of the bones were mostly not available because of the poor preservation. The following is description for relatively well-preserved adult remains and permanent teeth.

#### Face (Fig. 1, 1–3)

The glabellar swelling is weakly developed in general, and region of the nasal root is flattened in most individuals (Burial 22, 65, 80, 83, 93). The Burial 93 preserves the upper part of the nasal bones, which is narrow transversely.

#### Alveolar prognathism and occlusion (Fig. 1, 4)

All the three specimens with the alveolar process of the maxilla (Burial 13, 36, 82) show a strong degree of alveolar prognathism. The anterior tooth protrusion is also marked in two of them (Burial 36 and 82).

The sole individual whose occlusion can be reconstructed (Burial 36) show scissors occlusion. The anteroposterior molar relationship of this specimen is Class II, in which the maxillary molars occlude anteriorly relative to the mandibular counterparts. Other 17 individuals (Burial 2, 13, 22, 26, 30, 45, 63, 65, 66, 74, 80, 81, 82, 83, 93,

101a, 105) show distinct wear facets on the lingual faces of their maxillary anterior teeth, indicating that their anterior occlusal form was also scissors occlusion, although reconstruction of occlusion was not possible for these specimens. Some of them are inferred to have had deep overbite because the lingual tooth wear on their maxillary anterior teeth reach the basal tubercle. Neither edge-to-edge occlusion nor underbite is observed as far as the observed specimens are concerned.

#### Tooth wear (Fig. 1, 4–8)

The degree of occlusal wear on the teeth is such that molar cusp morphology is mostly obliterated at the stage of the early adulthood, with some of the specimens showing extensive dentine exposure. In contrast, anterior tooth wear is relatively light. This overall pattern of occlusal tooth wear across the dentition is consistent with that of the general tendency seen in the Medieval Japanese from other regions (Kaifu, 1999a,b).

Obliquely oriented, abnormal wear is present on the mesiolingual aspect of the maxillary right second premolar of Burial 74. Apparently, this was not caused by occlusion with the mandibular teeth, and probably was a consequence of some way of use of the teeth as a tool. Unusually oblique wear is also present on the maxillary left central incisor of Burial 93, although it is not clear whether this reflects a non-masticatory use of the teeth in this individual because the mandibular antagonists are missing.

#### Lower limb bones

The linea aspera of the femur is relatively well-developed. Of the four specimens in which the linea aspera is preserved, at least three are males (Burial 13, 22, 74) and the remaining one is of indeterminate sex (Burial 100). The shaft of the tibia is moderately wide transversely in most individuals (Burial 44, 65, 74, 92B, 105), while one shows some degree of platychemic tendency (Burial 26, adult female).

Table 3. Preservation of the dentition and mesiodistal tooth dimension (mm).

Specimen (Age and sex)	Jaw	Right										Left						
		M3	M2	M1	P2	P1	C	I2	I1	II	I1	I2	C	P1	P2	M1	M2	M3
Cremation 5 (Early adulthood)	U														○	△	△	×
Cremation 14 (Adult)	L																	
Cremation 35 (Early adulthood)	U	8.5		11.0												11.0		
Burial 1 (Adult)	U	9.6	10.4				6.8							7.0				CF
Burial 2 (?Early adulthood female)	L	3.7	9.3	10.9	6.4	7.0	7.8	6.6	8.4	8.7	6.2	7.6	7.1	6.5	10.3			
Burial 3 (Early to late adulthood)	L	9.2	10.1	10.6	7.1	×	6.5	5.7	5.0	5.1	5.9	6.6	△	6.8	10.7	10.5		
Burial 9 (Early to late adulthood)	U		11.7	12.0	7.2													
Burial 13 (?Early adulthood male)	L		9.0	×	×	○	○	○										
Burial 18 (Early to late adulthood)	U		9.7	11.5	6.8	6.8	7.8	6.8	8.8	8.5	6.8	7.8	6.8	6.9	10.6	9.7	8.2	
Burial 22 (?Early to late adulthood male)	L	×	11.0	11.1	6.9	6.9	7.2	6.0	5.3	5.2	5.8	7.1	7.1	7.2	11.4	11.1	○	
Burial 24 (Young adult)	U																	
Burial 26 (Early to late adulthood female)	L		×		7.0	7.6	7.9	7.0	8.7	8.7		7.7	7.6	6.8	10.7			
Burial 27 (Early adulthood)	U	8.9	9.9	10.3	7.1	6.5	6.7					7.5	6.9	6.5	11.0			
Burial 30 (Early to late adulthood male)	L	9.8	11.4	11.3	6.9	7.1												
Burial 34 (Early to late adulthood)	U	8.2	×		6.0	7.0	8.1	7.6		9.0	○		7.2	7.8				
Burial 35 (Early adulthood)	L	10.9	10.8	11.2	7.1	6.7	7.0	○					7.0	7.0	12.0	10.6		
Burial 36 (Early adulthood male)	U																	
Burial 43 (Early adulthood)	L																	

Table 3. (Continued)

Specimen (Age and sex)	Jaw	Right											Left												
		M3	M2	M1	P2	P1	C	I2	II	I1	I2	C	P1	P2	M1	M2	M3								
Burial 44 (Adult)	U			11.1							7.2			7.8	7.2	7.4	7.4	7.7	7.0		11.7				
Burial 45 (Early adulthood)	L						6.6	5.3	5.3	5.9			—			6.8					7.0				10.7
Burial 63 (Early adulthood)	U	7.3	8.3	10.5	6.6	6.9	7.3	6.0	8.0	6.0				7.8	5.8	7.6		7.0		6.6	12.0			6.8	
Burial 65 (Early adulthood male)	L	9.5	10.1	11.3	6.3	6.3	6.3	5.7	5.2	5.7				5.0	5.9	6.5		6.5		6.5	11.4			9.7	
Burial 66 (14-16 years)	U	8.3	9.4	—	6.3	7.2	7.3	7.0	8.2	7.0				8.3	7.3	7.5		7.2		6.3	10.5			8.7	
Burial 70 (Early adulthood)	L	9.7	—	10.5	6.5	7.5	6.8	5.8	5.4	5.8				7.7	6.5	7.4		7.4		6.4	10.8			9.8	
Burial 74 (Late adulthood male)	U	8.6	9.5	10.1	6.6	6.6	7.4	6.4	7.5	6.4				5.1	5.4	7.4		6.8		6.5	10.7			8.7	
Burial 77 (Early adulthood female)	L	10.0	11.0	10.8	6.8	6.7	6.7	6.7		6.7						6.6		—		6.8	10.8			10.4	
Burial 78 (?Early adulthood female)	U													8.6		—		7.5		7.4					
Burial 80 (?Early adulthood female)	L	8.9	9.6	—	7.6	7.8	7.1	6.1	8.7	7.6				—	6.2	—		7.3		×				10.3	
Burial 81 (Early adulthood)	U						—	—	—	—						—		6.3		6.3					
Burial 82 (Early adulthood female)	L						6.2	6.2	5.3	6.2				8.5				6.7		6.4	10.0			8.3	
Burial 83 (Early adulthood)	U	6.9	—	9.5	6.5	7.0	7.1	6.1	5.3	6.1				8.2	5.3	7.0		6.5		6.3	10.6				
Burial 84 (Early adulthood male)	L	8.0	10.0	10.8	7.0	6.9	5.9	5.5	5.0	5.5				5.5	5.5	6.2		7.1		7.2	10.8			8.3	
Burial 85 (Early to late adulthood female)	U	—	—	—	7.6	7.6	7.6	6.4	8.6	8.0				8.6		8.0		6.9		6.8	11.4				
Burial 86 (Early adulthood male)	L	8.3	—	—	8.3	7.3	7.0	6.4	5.4	6.2					6.2	6.8		7.4		7.9					
Burial 89 (Young to early adulthood)	U	10.4	12.7	12.3	7.6	7.8	8.1	6.8		7.3						7.3		7.3		7.0	11.5				
Burial 91 (Early adulthood)	L	8.4	9.0	10.6	6.7	7.0	—	—	9.0	—						—		—		6.7	11.6			7.5	
	U						—									—			7.4		11.0				
	L	9.4	10.2	—	—	—	—	—	—	—						—			7.2		7.2	11.9			
	U						—	—	—	—									7.0		7.0	10.8			
	L						—	—	—	—										—	11.5				



Table 3. (Continued)

Specimen (Age and sex)	Jaw	Right									Left							
		M3	M2	M1	P2	P1	C	I2	II	I1	I2	C	P1	P2	M1	M2	M3	
Burial 92A (Early adulthood)	U		9.7	10.7	6.5													8.7
Burial 92B (Adult)	L			10.3		6.3	5.9											10.7
Burial 93 (Early to late adulthood male)	U	7.3	×	11.0	7.3	7.2	×	×		○	6.7	7.0	7.0	11.1	×			
Burial 97 (Early adulthood)	L	8.7	×	11.8	-	-	×	×		×	×	6.9	6.9	10.7	×			
Burial 101a (15-20 years male)	U	9.6		11.4	6.7			8.8	8.9	7.3	7.6	7.4	7.1	11.5		11.0	10.0	
Burial 101b (Early adulthood female)	L	11.2	10.8	12.0						6.4	7.3	7.5	7.0	11.7	10.8	6.0		
Burial 104 (Early to late adulthood)	U					6.5								10.8	10.6	9.8		
Burial 105 (Early to late adulthood)	L	9.0							8.4	6.8				11.3				
Burial 106 (Early adulthood)	U													11.6				
Burial 108 (Early adulthood)	L					6.6		6.9	8.5	6.8		6.6	6.3	○	11.4			
Burial 109 (14-16 years)	U					6.0							7.4	6.8	10.7	10.2		
Burial 115 (5-8 years)	U												6.9	6.8	11.1	10.6	CF	
	L												6.9	6.4	8.9	8.9	8.6	
	U									5.9	6.7	6.6	6.5	10.7	9.3	8.6	8.6	
	L													11.2	10.2	8.7	8.7	
	U																	
	L																	

(-), the tooth is present but not measurable because of the damage; ○, the tooth is missing but the alveolus is normal; △, the alveolus is in the process of resorption; ×, the alveolus is resorbed; CF, the presence of the tooth is confirmed by the interproximal wear facet of an adjacent tooth. E, developing tooth which cannot be measured.

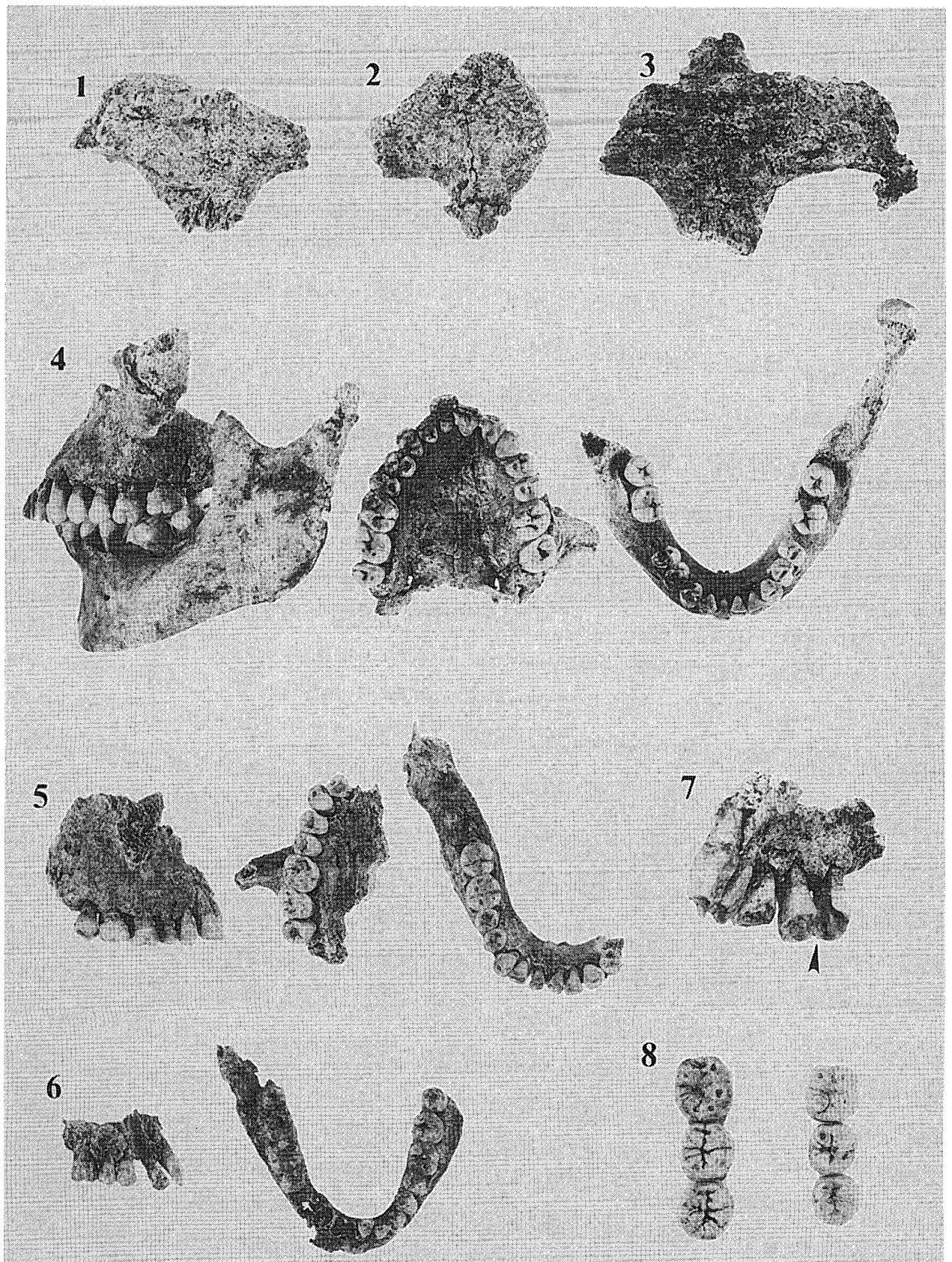


Fig. 1. 1-3, Glabellar region of the frontal of Burial 65, 83, and 93, respectively; 4, from left to right, lateral view of the maxilla and mandible in occlusion, occlusal view of the maxilla, and occlusal view of the mandible of Burial 36; 5, from left to right, lateral view of the maxilla, occlusal view of the maxilla, and occlusal view of the mandible of Burial 13; 6, lateral view of the maxilla (left) and occlusal view of the mandible (right) of Burial 82; 7, Abnormal tooth wear on the second premolar of Burial 74; 8, The molar rows of the two individuals found from the Burial grave 101 (left, Burial 101a, and right, Burial 101b).

### Oral and other pathology (Fig. 1, 4–6)

Dental caries is found in 58 out of 587 sufficiently preserved teeth, and is about 10% in frequency. Fujita and Suzuki (1995) reported that caries is most frequently observed on the cervical part of the tooth's buccal face in the prehistoric Jomon hunter-gatherers, whereas in modern Japanese it usually occurs at the interproximal spaces or in occlusal grooves and pits of the crown. The caries of the human remains from the Obusato Site 20th Locality is most frequently observed, as in the pattern of modern Japanese, at the interproximal spaces or on the occlusal surface of the crown.

Antemortem loss of molar(s) and subsequent resorption of the alveolar bone are seen in many individuals (Table 3). Most individuals of the present sample are thought not to have reached advanced ages (Table 1). Therefore, in conjunction with the dental caries frequency which is moderately high, oral hygiene was relatively poor in this population.

Burial 65, an early adulthood male, has an amorphous, possible supernumerary tooth which is still developing, although this possibility cannot be confirmed owing to its isolated condition and incomplete preservation of the jaw bones. Periostritis-like modification is observed on the right and left tibiae of Burial 74 (late adulthood male), but the preservation is too poor to obtain further details.

### Longevity

Only rough estimates of age are available for most of the adult specimens in Table 1, because the estimation is mostly based on the degree of tooth wear. Nevertheless, Table 1 largely indicates that individuals in early adulthood represent a core portion of the population, suggesting relatively short longevity of ordinary people during the late Medieval to early Edo periods in this region.

### Organization of the burials

Because the remains from the cremation graves are too fragmentary, the following discus-

sion is focused only on the burial graves. In the case where burial position is confirmed, all the buried individuals were, without exception, in a flexed posture with their heads oriented north (Burial 3, 13, 22, 26, 30, 36, 63, 65, 74, 80, 82, 86, 92A, 93, 105, 108, 109). This orientation of the head probably applies to other graves in which only dental remains were preserved, because these remains were discovered from a northern location in each grave. Most of these individuals were laid on their right side down to the ground.

Dentitions of two individuals were identified from the Burial grave 101 (Fig. 1, 8). Because this grave had no overlap with the other graves, it probably represents a double burial. A likely case of double burial has also been reported from an adjacent graveyard around the Muromachi period at the Dojo Jiin Site (Kaifu *et al.*, 1998). The number of graves with identifiable human remains now amounts to more than 60 adding the two sites, but the above-mentioned two are the only confirmed instances of double burials. Therefore, it is likely that the people in this region. This situation suggests that single burial was popular among the people in this region around the Muromachi period, whereas double burial was given on rare occasions. However, preservation of the human remains is generally poor at both sites, and this possibility needs to be further tested in future with a larger sample. The tooth size suggests that the two individuals from the Burial grave 101 of the present site are young adult male and early adulthood female.

Among the individuals whose sex could be reasonably estimated, 10 were males and 8 were female, suggesting no significant bias in sex ratio. Graves of the male and female individuals seem to be distributed at random within the graveyard.

Among the 53 individuals with known age at death, the number of juvenile individual is only one (Burial 115). The rest of the individuals are young adult or older, about 90% of which being adult or at least close to the adulthood. This situation suggests that remains of subadult individu-

als were not preserved in this graveyard because they are less robust than those of adults, or otherwise indicates that this graveyard was mainly that for adults. A similar case is also reported for the above-mentioned adjacent graveyard site (Kaifu, *et al.*, 1998). However, this possibility should be tested in future studies because only half of the detected graves preserved human remains whose age could be reasonably estimated. The grave of the sole juvenile individual from the Obusato Site 20th Locality was somewhat small compared to the other graves in which human remains were preserved. Quite a few such relatively small graves have been detected in the graveyard, but no human remains were found from them.

### Summary and Conclusions

The small sample of the skeletal remains from the graveyard at the Obusato Site 20th Locality was similar in a series of characters to those of historic populations of the Kanto region. Such features include a relatively flattened region of the glabella and nasal root, scissors occlusion, and a more or less wide tibial shaft. These are consistent with characters typically observed in people of the protohistoric or historic eras in the Kanto region, and contrast with those commonly observed in the people of the prehistoric Jomon period. The severity of the anterior tooth wear is apparently lighter compared to the average condition in the protohistoric period, and close to the populations in the later periods. The strong alveolar prognathism seen in the remains of the present site is also a characteristic of the medieval and later Japanese populations (Kaifu, 1999c). The degree of posterior tooth wear was apparently heavier than later inhabitants in the City of Edo, and is closer to the general tendency of the Medieval Japanese, although this is not statistically evaluated because of the sample size restriction. In summary, the human remains from the Obusato Site 20th Locality generally show a

series of previously documented characteristics of the Medieval people of the Kanto region.

The condition of oral hygiene was probably poor as suggested from high frequencies of dental caries and periodontal disease. Similarly, the longevity was inferred to have been significantly short compared to the condition in modern Japanese.

The burial posture observed at the site was a flexed posture with their head oriented north, and right side down to the ground. At present, there is no compelling evidence of bias in sex and age compositions within the graveyard. Although single burial was dominant, double burial may have been given sometimes around the Muromachi period in this region.

### References

- Fujita, H. and T. Suzuki, 1995. Dental caries in the Jomon people. *Koukougakuzatsi*, **80**: 95–107.
- Fujita, K., 1949. On the standard for measurement of teeth. *J. Anthrop. Soc. Nippon*, **61**: 27–32. (In Japanese.)
- Kaifu, Y., 1999a. Changes in the pattern of tooth wear from the prehistoric to recent periods in Japan. *Am. J. Phys. Anthropol.*, **109**: 485–499.
- Kaifu, Y., 1999b. Tooth wear of a medieval Japanese population from the Yoshimohama site. *Bull. Natn. Sci. Mus., Tokyo, Ser. D*, **25**: 41–48.
- Kaifu, Y., 1999c. Changes in alveolar prognathism and anterior teeth protrusion. *Anthropol. Sci.* **107**: 3–24.
- Kaifu, Y., K. Sakaue, and H. Yamada, 1998. Human skeletal remains from the Dojo Jiin Site. In: Urawa City Iseki-Chosakai (ed.), *The Dojo Jiin and the Okuboryoke Sites, Reports of the Urawa City Iseki-Chosakai*, 237, pp. 120–127. (In Japanese.)
- Meindl, R. and C. O. Lovejoy, 1985. Ectocranial suture closure: A revised method for the determination of skeletal age at death based on the lateral-anterior sutures. *Am. J. Phys. Anthropol.*, **68**: 57–66.
- Scott, R. G. and C. G. Turner II, 1997. *The Anthropology of Modern Human Teeth*. Cambridge University Press, Cambridge.
- Ubelaker, D. H., 1989. *Human Skeletal Remains*, 2nd ed. Taraxacum, Washinton.